

This paper was presented at the National Academy of Sciences colloquium “The Neurobiology of Pain,” held December 11–13, 1998, at the Arnold and Mabel Beckman Center in Irvine, CA.

## A visceral pain pathway in the dorsal column of the spinal cord

WILLIAM D. WILLIS\*†, ELIE D. AL-CHAER\*‡, MICHAEL J. QUAST\*§, AND KARIN N. WESTLUND\*

Departments of \*Anatomy and Neurosciences, §Radiology, and ‡Internal Medicine, University of Texas Medical Branch, Galveston, TX 77555

**ABSTRACT** A limited midline myelotomy at T10 can relieve pelvic cancer pain in patients. This observation is explainable in light of strong evidence in support of the existence of a visceral pain pathway that ascends in the dorsal column (DC) of the spinal cord. In rats and monkeys, responses of neurons in the ventral posterolateral thalamic nucleus to noxious colorectal distention are dramatically reduced after a lesion of the DC at T10, but not by interruption of the spinothalamic tract. Blockade of transmission of visceral nociceptive signals through the rat sacral cord by microdialysis administration of morphine or 6-cyano-7-nitroquinoxaline-2,3-dione shows that postsynaptic DC neurons in the sacral cord transmit visceral nociceptive signals to the gracile nucleus. Retrograde tracing studies in rats demonstrate a concentration of postsynaptic DC neurons in the central gray matter of the L6-S1 spinal segments, and anterograde tracing studies show that labeled axons ascend from this region to the gracile nucleus. A similar projection from the midthoracic spinal cord ends in the gracile and cuneate nuclei. Behavioral experiments demonstrate that DC lesions reduce the nocifensive responses produced by noxious stimulation of the pancreas and duodenum, as well as the electrophysiological responses of ventral posterolateral neurons to these stimuli. Repeated regional blood volume measurements were made in the thalamus and other brain structures in anesthetized monkeys in response to colorectal distention by functional MRI. Sham surgery did not reduce the regional blood volume changes, whereas the changes were eliminated by a DC lesion at T10.

Visceral pain caused by cancer of pelvic organs can be difficult to manage even with high doses of morphine. Neurosurgical approaches to this problem have included anterolateral cordotomy to interrupt the spinothalamic tract and related associated pathways (see ref. 1 for review). However, visceral pain is often bilateral in origin, and bilateral cordotomies can produce undesirable complications. Commissural myelotomy was introduced as a means to interrupt the crossing axons of the spinothalamic tract over several segments without damaging long tracts in the lateral funiculus. However, commissural myelotomy also can result in unwanted side effects (1). Limited midline myelotomy at C1 was found to be surprisingly effective in relieving pain in distant parts of the body (2, 3). The proposed rationale for this procedure was interruption of a hypothetical multisynaptic pain transmission system in the central gray region of the spinal cord (3). For pelvic cancer pain, a limited midline myelotomy at T8–10 has been reported to be effective with minimal side effects (4–6).

### Ascending Pathways that Mediate Visceral Nociceptive Transmission

In one particularly well-documented clinical case, a patient who was treated successfully by a limited midline myelotomy

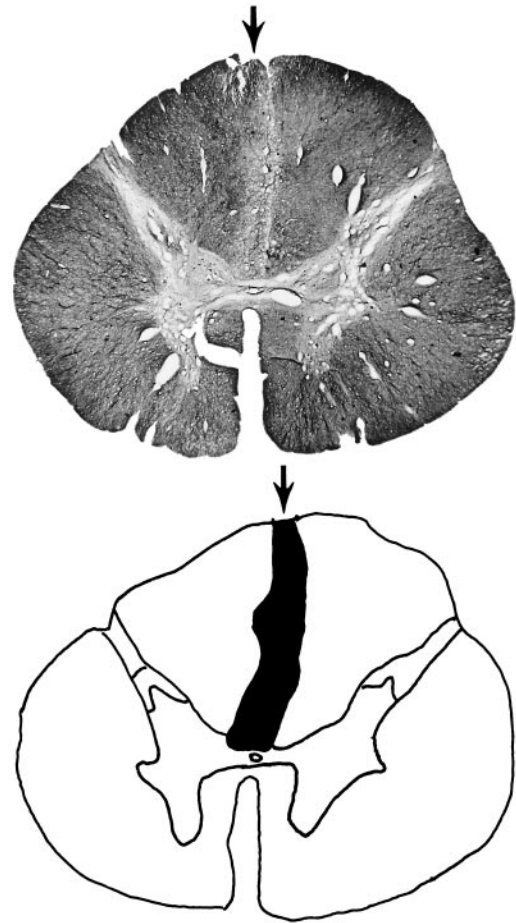


FIG. 1. Transverse section of the spinal cord of a patient whose colon cancer pain was relieved by a limited midline myelotomy at T10. The section was taken at a level just rostral to the site of the lesion and was stained for myelin. A bilateral demyelinated area in the fasciculus gracilis is seen below the arrow. The drawing shows the demyelinated area in black. [Figure reproduced with permission from ref. 5 (Copyright 1996, International Association for the Study of Pain).]

had colon cancer pain that was not relieved by large doses of morphine delivered i.v. by using a patient-controlled analgesia pump (5). After the myelotomy was done at T10, the cancer pain was totally relieved, and the morphine was discontinued over 3 days. The patient died in 3 months without recurrence of the visceral pain and without need for pain medication. His spinal cord became available for postmortem study and it was

Abbreviations: CRD, colorectal distention; DC, dorsal column; VLC, ventral lateral column; VPL, ventral posterolateral nucleus.

†To whom reprint requests should be addressed at: University of Texas Medical Branch, 301 University Boulevard, Galveston, TX 77555-1069. e-mail: wdwillis@utmb.edu.

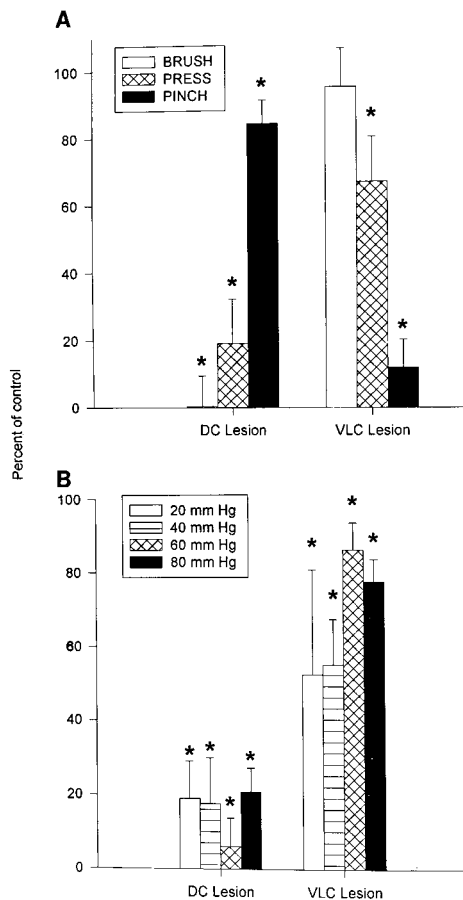


FIG. 2. Effects of DC and VLC lesions at T10 in rats ( $n = 20$ ) on responses to mechanical stimulation of the skin (Brush, Press, and Pinch) and to graded intensities of CRD (20, 40, 60 and 80 mm Hg). The responses were normalized. \* indicates a significant change. [Figure reproduced with permission from ref. 7 (Copyright 1996, The American Physiological Society).]

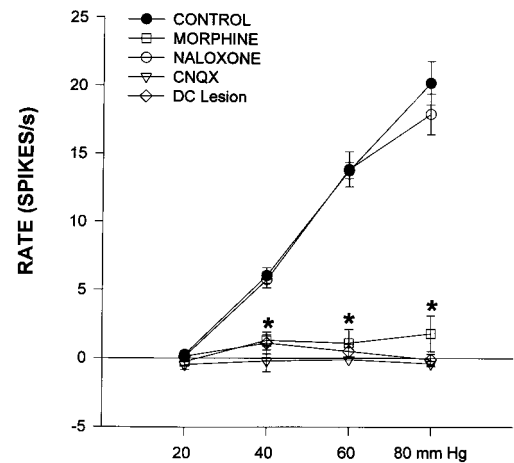


FIG. 3. Effects of microdialysis administration of drugs that block nociceptive synaptic transmission into the sacral spinal cord on responses of gracile neurons ( $n = 10$ ) to graded intensities of CRD. The drugs included morphine and CNQX (6-cyano-7-nitroquinoline-2,3-dione). Naloxone was given systemically to reverse the action of morphine. In some animals ( $n = 3$ ), a lesion was placed in the DC. \* indicates a significant change. [Figure reproduced with permission from ref. 11 (Copyright 1996, The American Physiological Society).]

determined that the surgical lesion interrupted the medial fasciculus gracilis bilaterally, as shown in Fig. 1. The lesion did not appear to intrude into the central gray matter.

Experimental studies therefore were begun to determine whether there is a visceral nociceptive pathway in the dorsal column (DC). Recordings were made in the ventral posterolateral (VPL) nucleus of the rat thalamus from neurons that responded to colorectal distention (CRD) or to inflammation of the colon (5, 7). The neurons also responded to mechanical stimuli applied to the skin. Sequential lesions of the DC and the spinothalamic tract in the ventrolateral column (VLC) were made to see whether these affected the responses to noxious stimulation of the colon or to stimulation of the cutaneous receptive field. A DC lesion was found to reduce the responses to CRD by 60–80%, whereas a VLC lesion only reduced such responses by 20% (Fig. 2B). The DC lesion also

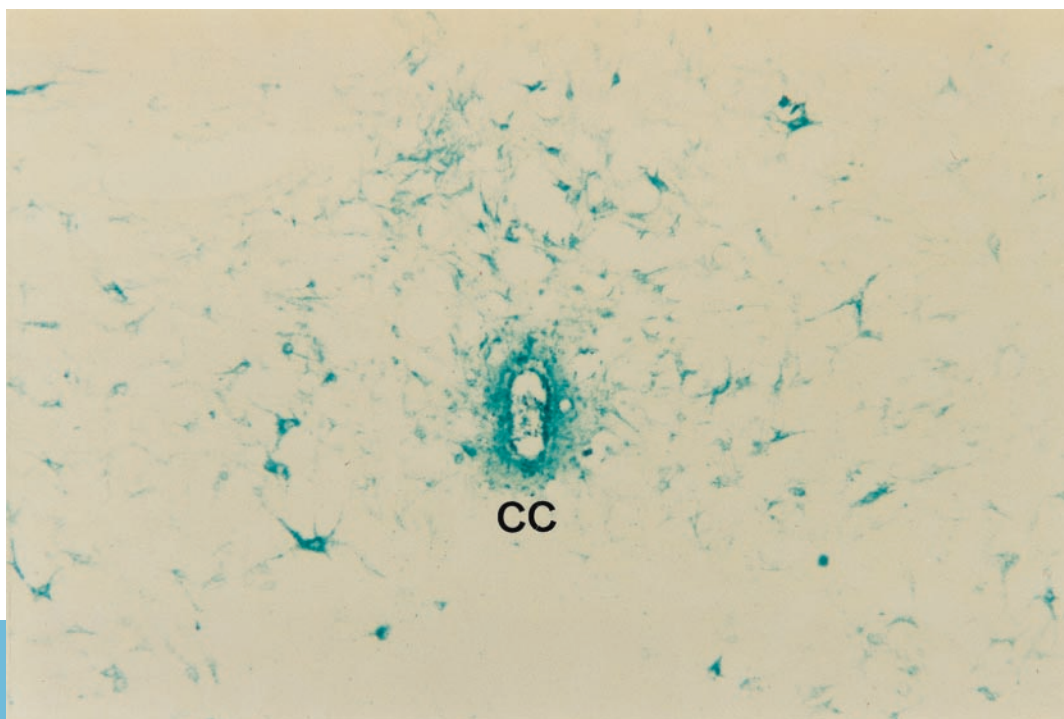


FIG. 4. Morphological studies of the origins of axons in the medial DC that might mediate the transmission of visceral nociceptive information. The retrograde tracer, WGA-HRP, was injected into the DCs at the cervical level, taken up by axons, and transported caudally to label numerous cell bodies in the central region of the spinal cord adjacent to the central canal (CC). [Figure reproduced with permission from ref. 5 (Copyright 1996, International Association for the Study of pain).]

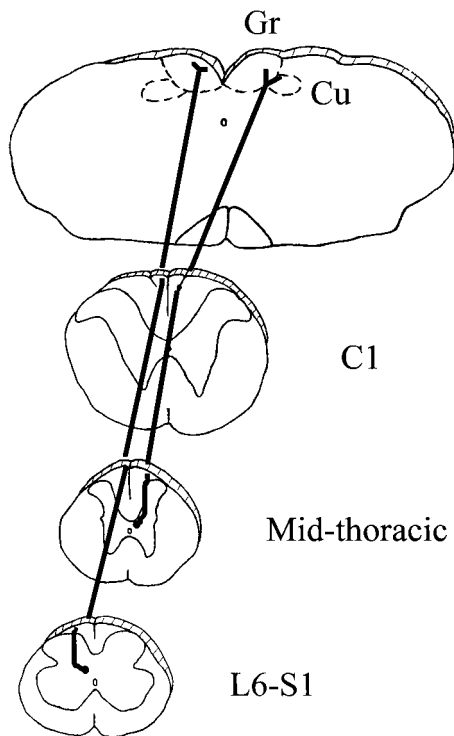


FIG. 5. Summary diagram depicting the course of axons arising from postsynaptic DC neurons in the visceral processing region adjacent to the central canal. Axons arising from neurons near the central canal at sacral levels of the spinal cord ascend in the midline of the DC adjacent to the medial septum to innervate the medial gracile nucleus. Axons arising from neurons near the central canal at thoracic levels of the spinal cord ascend in the DC adjacent to the dorsal intermediate septum and innervate both the gracile and cuneate nuclei.

profoundly reduced the responses to weak stimulation of the skin but had little effect on those to noxious pinch (Fig. 2A). A VLC lesion nearly eliminated responses to pinch but had only limited effects on responses to weak stimulation of the skin. A DC lesion also reduced the heightened activity of VPL neurons after colon inflammation; a VLC lesion had much less effect. A small electrolytic or kainic acid lesion in the gracile nucleus dramatically reduced the responses of VPL neurons to CRD (8). It was concluded that the DC is more important than the VLC for transmitting nociceptive signals from the colon to the VPL nucleus (7). Similar results with respect to CRD were obtained in monkeys (9).

The visceral nociceptive signals that reach the gracile nucleus could be transmitted by the collaterals of primary afferent neurons that ascend directly to the gracile nucleus or by the axons of postsynaptic DC neurons (see review in ref. 10). Which of the routes was the more effective was tested by blocking nociceptive transmission from the colon in the sacral spinal cord by using microdialysis administration of morphine or of the non-*N*-methyl-D-aspartic acid receptor antagonist CNQX (6-cyano-7-nitroquinoxaline-2,3-dione) (11). Access to the spinal cord by colon afferents was restricted to the pelvic nerve distribution by sectioning the hypogastric nerves bilaterally. Administration of either drug blocked the responses of gracile neurons to CRD (Fig. 3). Naloxone reversed the action of morphine. Similar effects were observed when recordings were made from identified postsynaptic DC neurons in the central gray region of the sacral cord. Neurons in this region are known to have a strong visceral input, and it proved to be the case for postsynaptic DC neurons located in this region. It was concluded that most of the responses of gracile neurons to CRD distention (or colon inflammation) depended on acti-

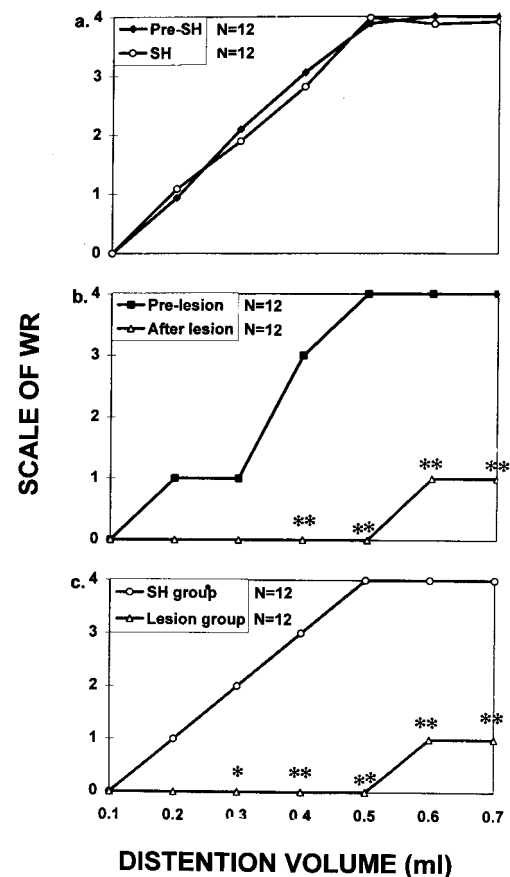


FIG. 6. Reduction in the writhing reflex (WR) evoked by balloon distention of the duodenum after a DC lesion. (a) The intensities of the WR evoked by graded distention (by 0.1 to 0.7 ml) of the duodenum are shown. No differences in the behavioral response were seen between rats tested before the sham surgery (pre-SH) and rats tested after the sham surgery (SH). The scale used was from 0 (normal) to 4 (stretching of the body, extension of the hind limbs). (b) The effect of the DC lesion on the behavioral response to duodenal distention is shown (prelesion vs. after lesion). (c) A comparison of the behavior in the sham surgery and lesion groups. The numbers of animals used are shown. \* indicate significant changes. [Figure reproduced with permission from ref. 13 (Copyright 1998, Lippincott Williams & Wilkins, <http://lww.com>).]

vation of postsynaptic DC neurons, although it could not be ruled out that some of the responses were the result of conduction in directly projecting primary afferents.

### Morphological Studies of the Visceral Postsynaptic DC System

The cells of origin of the midline DC pathway and their brainstem terminations have been identified anatomically (Figs. 4 and 5). The injection of a retrograde tracer, WGA-HRP, into the DC at an upper cervical level labeled a large number of postsynaptic DC neurons in the central gray and surrounding area at all levels of the spinal cord examined (5). Unpublished studies have shown that retrograde label microinjected into the medial aspect of the gracile nucleus also labels a large population of postsynaptic DC neurons in the region of the central gray at sacral levels.

Injection of an anterograde tracer, biotin dextran, into the central gray region of the sacral cord labeled axonal projections from this region that ascend in the fasciculus gracilis near the midline and have terminal arbors in the medial part of the gracile nucleus (5). These observations were confirmed by small injections of *Phaseolus vulgaris* leucoagglutinin as the

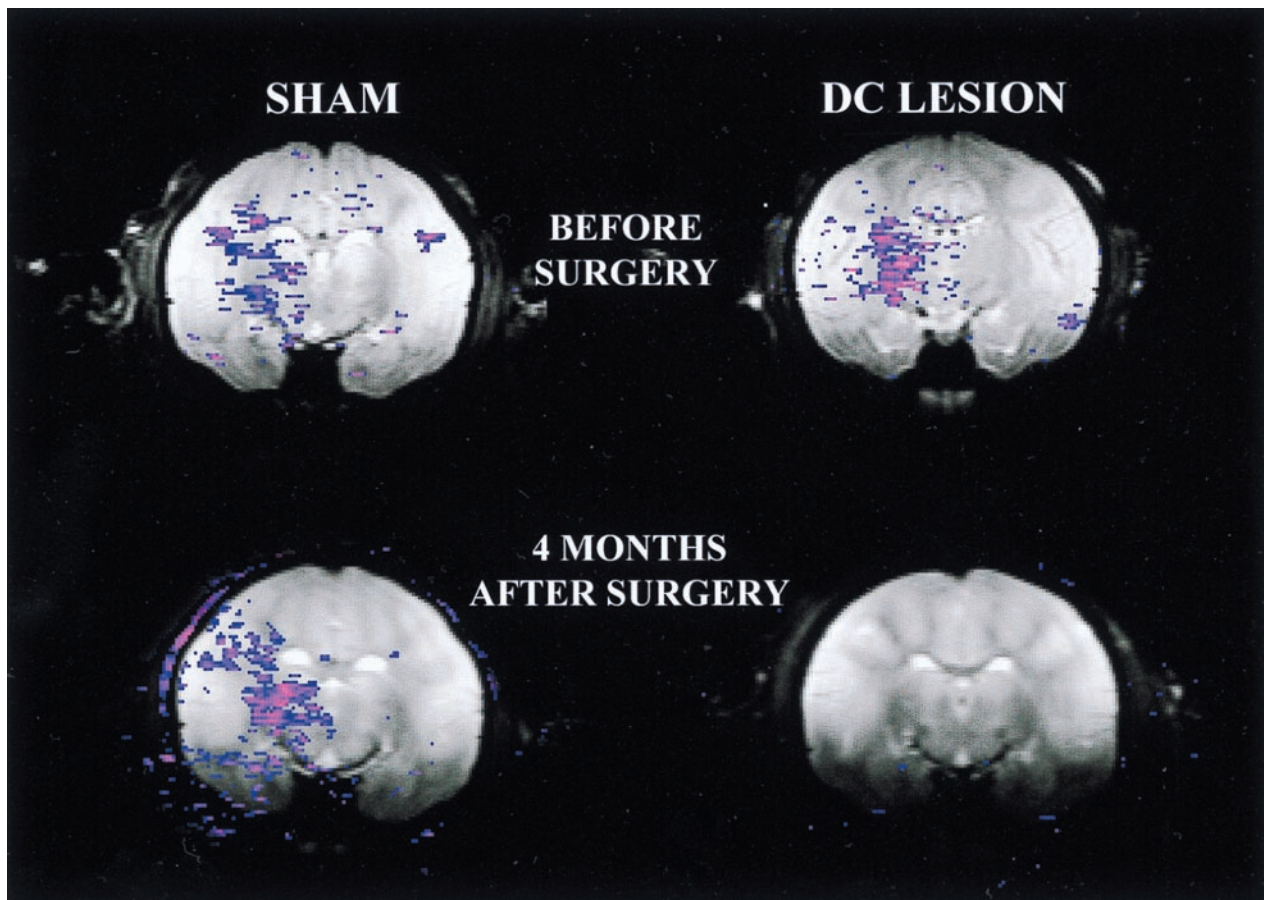


FIG. 7. Functional MRI (fMRI) study of the effects of a DC lesion on blood volume changes evoked in the brain after noxious distention of the colon in monkeys. (*Left*) The brain slices shown were taken from a monkey that was subjected to sham surgery at T10. The fMRI images were from a comparable location before (*Upper*) and then 4 months after the sham surgery (*Lower*). (*Right*) The images were made before and 4 months after a DC lesion at T10 in a different monkey. Colored regions indicate locations where regional cerebral blood volume increased relative to the nonstimulated state.

anterograde tracer made into the central canal region of the sacral cord (C.-C. Wang, W.D.W., and K.N.W., unpublished work). The visceral postsynaptic DC pathway arising from the sacral spinal cord ascends in the DC midline adjacent to the medial septum. Similar injections into the central gray region at a midthoracic level label axons that ascend adjacent to the dorsal intermediate septum. These axonal projections also have terminations in the gracile and cuneate nuclei. A summary diagram representing these pathways is shown in Fig. 5.

#### Behavioral Evidence for a DC Visceral Pain Pathway

To determine whether the DC helps mediate pain originating in abdominal viscera, experiments were done in awake, behaving rats on the effects of a DC lesion on the behavioral responses to pancreatitis and noxious chemical stimulation of the pancreas and to duodenal distention.

A pancreatitis model induced by infusion of glycodeoxycholic acid into the pancreas and i.p. caerulein was shown to reduce home-cage exploratory behaviors (rearing) in rats (12). Decreases in normal activity did not occur in animals that had received lesions of their DC at the C1 spinal level 1 week before induction of the pancreatitis, suggesting that the DC lesion provided a protective effect. More recent unpublished data confirmed that responses of VPL neurons to stimulation of the pancreas with bradykinin also are reduced by a DC lesion and also by spinal administration of morphine at a midthoracic level. The effect of morphine is naloxone reversible.

In another series of experiments, a balloon catheter was chronically implanted in the duodenum in rats through the

stomach wall (13). Graded distention of the duodenum in awake, behaving animals resulted in graded intensities of the writhing reflex. A lesion of the DC at C2 produced a dramatic reduction in the intensity of the writhing reflex (Fig. 6). However, to be effective, the lesion had to include the region of the dorsal intermediate septum bilaterally. Parallel experiments were done in anesthetized rats to determine the effects of a DC lesion at C2 on the responses of VPL neurons to duodenal distention. Again, a lesion of the DC that included the region of the dorsal intermediate septum bilaterally resulted in a profound reduction in the responses of the VPL neurons. The requirement for the placement of the DC lesions laterally to the midline is explained by the morphological study described in the previous section and illustrated in Fig. 5. Axons originating from postsynaptic dorsal horn neurons in the central gray region of the midthoracic spinal cord travel toward the DC nuclei near the dorsal intermediate septum.

#### Functional MRI Studies in Monkeys

In a recent unpublished study, the brain structures involved in mediating visceral nociceptive responses have been investigated by using functional MRI. Monkeys were anesthetized with isoflurane and placed in a 4.7-Tesla magnet for imaging regional cerebral blood volume. The blood was labeled with a superparamagnetic iron oxide compound to enhance the contrast in the image in proportion to increases in regional blood volume. Relative cerebral blood flow was estimated by gradient echo bolus tracking, and changes in cerebral blood volume were estimated by steady-state spin echo imaging. Noxious

CRD consistently caused regional blood volume increases in a number of brain structures, including the VPL nucleus. Blood volume changes were not reduced after sham surgery, but they were essentially completely eliminated after the DC lesion. The effects of the DC lesion persisted for at least 4 months (Fig. 7).

We thank Kelli Gondesens and Jingna Wei for their expert technical assistance. The work was supported by National Institutes of Health Grant NS 11255.

1. Gybels, J. M. & Sweet, W. H. (1989) *Neurosurgical Treatment of Persistent Pain* (Karger, Basel).
2. Hitchcock, E. R. (1970) *J. Neurol. Neurosurg. Psychiatry* **33**, 224–230.
3. Schvarcz, J. R. (1984) *Acta Neurochir.* **33**, Suppl., 431–435.
4. Gildenberg, P. L. & Hirshberg, R. M. (1984) *J. Neurol. Neurosurg. Psychiatry* **47**, 94–96.
5. Hirshberg, R. M., Al-Chaer, E. D., Lawand, N. B., Westlund, K. N. & Willis, W. D. (1996) *Pain* **67**, 291–305.
6. Nauta, H. J. W., Hewitt, E., Westlund, K. N. & Willis, W. D. (1997) *J. Neurosurg.* **86**, 538–542.
7. Al-Chaer, E. D., Lawand, N. B., Westlund, K. N. & Willis, W. D. (1996) *J. Neurophysiol.* **76**, 2661–2674.
8. Al-Chaer, E. D., Westlund, K. N. & Willis, W. D. (1997) *J. Neurophysiol.* **78**, 521–527.
9. Al-Chaer, E. D., Feng, Y. & Willis, W. D. (1998) *J. Neurophysiol.* **79**, 3143–3150.
10. Willis, W. D. & Coggeshall, R. E. (1991) *Sensory Mechanisms of the Spinal Cord* (Plenum, New York).
11. Al-Chaer, E. D., Lawand, N. B., Westlund, K. N. & Willis, W. D. (1996) *J. Neurophysiol.* **76**, 2675–2690.
12. Houghton, A. K., Kadura, S. & Westlund, K. N. (1997) *Neuro-Report* **8**, 3795–3800.
13. Feng, Y., Cui, M., Al-Chaer, E. D. & Willis, W. D. (1998) *Anesthesiology* **89**, 411–420.